

Cardiopancreatic Effects of *Artocarpus heterophyllus* in Mercury Chloride-Exposed Wistar Rats: Biochemical and Histological Evidence

Edobor Obayuwana, Joseph Raymond Enoghase*

Department of Anatomy, University of Benin, Nigeria.

Corresponding author*

joseph.enoghase@uniben.edu

Manuscript received: 03 February 2026. Revision accepted: 01 June 2026, Published: 17 June 2026.

Abstract

Mercury chloride (HgCl₂) is a pervasive environmental toxicant that disrupts redox balance and induces structural injury in metabolically active organs, including the heart and pancreas. *Artocarpus heterophyllus* (jackfruit) contains antioxidant phytochemicals, while vitamin E is an established antioxidant; both may counteract mercury-induced toxicity. This study evaluated the protective effects of aqueous *Artocarpus heterophyllus* fruit extract and vitamin E on cardiac and pancreatic alterations in HgCl₂-exposed Wistar rats. Twenty-five adult Wistar rats (180–200 g) were randomly assigned into five groups (n = 5): control; HgCl₂ (3 mg/kg); *Artocarpus heterophyllus* extract (1000 mg/kg); extract + HgCl₂ (extract administered 30 min before HgCl₂); and vitamin E (200 mg/kg) + HgCl₂ (30 min prior). Treatments were given orally once daily for 28 days. Body weights were recorded weekly. At sacrifice, heart and pancreas weights were measured and organ-to-body weight indices calculated. Serum antioxidant markers—superoxide dismutase (SOD), catalase (CAT), glutathione peroxidase (GPx), and malondialdehyde (MDA)—were assayed. Lipid profile parameters (total cholesterol [TC], triglycerides [TG], HDL-C, and LDL-C) were determined using commercial kits. Cardiac and pancreatic tissues were examined histologically using hematoxylin and eosin staining. Data were analyzed by one-way ANOVA with LSD post-hoc tests (p < 0.05). All animals completed the study. Phytochemical analysis of *Artocarpus heterophyllus* extract showed high total phenolic (29 ± 0.48) and flavonoid (5.4 ± 1.2) contents, with appreciable levels of saponins (19 ± 1.1), tannins (4.7 ± 0.41), and alkaloids (0.70 ± 0.09). Body weight increased significantly in the control group (p = 0.005), whereas HgCl₂-treated rats showed minimal weight change (p = 0.777). Heart and pancreas weights and indices did not differ significantly among groups (p > 0.05). HgCl₂ significantly reduced serum SOD and CAT activities compared with control, while GPx activity showed a non-significant downward trend (p = 0.067). Serum MDA was highest in the HgCl₂ group, whereas extract- and vitamin E-treated groups showed marked reductions. HgCl₂ exposure decreased TC and HDL-C and increased TG (p < 0.001). Histologically, HgCl₂ induced interstitial haemorrhage and vascular congestion in the heart and vascular congestion with mild inflammatory infiltrates in the pancreas. These alterations were markedly attenuated by *Artocarpus heterophyllus* extract and vitamin E, with preservation of normal tissue architecture. Mercury chloride induced oxidative stress, dyslipidaemia, and structural injury in the heart and pancreas. Pre-treatment with phenolic-rich *Artocarpus heterophyllus* extract or vitamin E ameliorated these effects, supporting the antioxidant and tissue-protective potential of *Artocarpus heterophyllus* and warranting further mechanistic studies.

Keywords: *Artocarpus heterophyllus*; mercury chloride; heart; oxidative stress; lipid profile; pancreas.

INTRODUCTION

Mercury in the form of mercury chloride (HgCl₂) remains a significant environmental and occupational toxicant. Inorganic mercury has a strong affinity for sulfhydryl and seleno-groups, allowing it to bind cellular proteins, inhibit antioxidant enzymes, and disrupt mitochondrial activity. These actions promote excessive formation of reactive oxygen species (ROS) and initiate oxidative stress, lipid peroxidation, and cellular injury across multiple organs (Bondy, 2017; Balali *et al.*, 2021; Han *et al.*, 2022).

The heart is particularly vulnerable to toxic metals because of its high metabolic demand and constant

exposure to circulating xenobiotics. Experimental studies show that mercury interferes with calcium handling in cardiomyocytes, suppresses ATP-dependent ion transporters, impairs endothelial function, and increases susceptibility to hypertension and arrhythmias (Martins *et al.*, 2021; Genchi *et al.*, 2017). The pancreas also demonstrates marked sensitivity to oxidative insults. β-cells possess relatively low intrinsic antioxidant capacity, making them highly susceptible to ROS-induced damage. Mercury exposure has been associated with increased oxidative load, down-regulation of endogenous antioxidant genes, impaired insulin secretion, and β-cell apoptosis (Yuliana *et al.*, 2024; Maqbool *et al.*, 2016).

Naturally occurring antioxidants have gained attention as potential countermeasures against heavy-metal toxicity. Jackfruit (*Artocarpus heterophyllus*) is widely consumed in tropical regions and is known to contain substantial quantities of phenolic compounds, flavonoids, carotenoids, and vitamin-rich phytochemicals. These constituents have demonstrated strong free-radical-scavenging and lipid-peroxidation-inhibiting effects in experimental models (Ajoboye *et al.*, 2016; Saha *et al.*, 2022; Hossain *et al.*, 2024). Extracts from various parts of the fruit, including the pulp and seeds, have shown high total phenolic content and significant antioxidant activity, attributed largely to compounds such as quercetin, catechins, and related polyphenols (Ramli *et al.*, 2021).

In view of the established oxidative mechanisms of mercury toxicity and the documented antioxidant potential of jackfruit, this study was designed to evaluate the protective effects of *Artocarpus heterophyllus* against HgCl₂-induced damage in the heart and pancreas of Wistar rats.

MATERIALS AND METHODS

Experimental Animals

Twenty-five (25) adult Wistar rats (180–200 g) were obtained from the Animal House of the Department of Anatomy, University of Benin, Nigeria. Animals were maintained under standard laboratory conditions (temperature 22 ± 2°C; relative humidity 50–60%; 12-h light/dark cycle) with unrestricted access to water and commercial rat pellets. A two-week acclimatization period preceded the experiment. All procedures conformed to institutional guidelines for the care and use of laboratory animals and were approved by the Research Ethic Committee of the college of Medical Sciences, University of Benin.

Rationale for Dose Selection

Mercuric chloride (HgCl₂) was administered at 3 mg/kg, a dose previously shown to induce measurable oxidative and histological toxicity in rat liver and kidney tissue without causing lethality (Ali *et al.*, 2020).

The *Artocarpus heterophyllus* extract dose of 1000 mg/kg was selected based on earlier studies reporting antioxidant and cytoprotective activity at this concentration (Osarinmwin and Ehimigbai, 2025). Vitamin E was used as a standard antioxidant control at a physiologically relevant dose (200 mg/kg), consistent with prior studies (Enoghase *et al.*, 2025; Obayuwana and Nweke, 2024).

Plant Collection and Extraction Procedure

Fresh fruits of *Artocarpus heterophyllus* were collected in Benin City and authenticated at the University of Benin Herbarium. Extraction followed cold maceration as described by Okoduwa *et al.* (2016). Briefly, shade-

dried leaves were pulverized, and 100 g of powder was soaked in 1 L of distilled water for 24 hours with intermittent agitation. The mixture was filtered and concentrated at 60°C using a water bath. Extract yield was recorded and the concentrate stored at 4°C until use.

Preparation of Extract for Administration

Ten grams (10 g) of the dried extract concentrate were homogenized in 100 mL of boiled, cooled distilled water and allowed to stand for 72 hours. After filtration, the resulting solution was stored in sterile, labeled bottles at 4°C. The extract was freshly prepared every 72 hours to preserve bioactivity.

Chemicals

Mercuric chloride (HgCl₂) of analytical grade was purchased from Emmytex Biomedical Store, Benin City. Vitamin E (alpha-tocopherol) capsules were obtained from a registered local pharmacy.

Experimental Design

Groups were designed to assess *A. heterophyllus* extract's protective effects against HgCl₂ toxicity, with Vitamin E as a reference antioxidant (not a chelation-specific control)

Animals were randomly assigned into five groups (n = 5):

- **Group 1 (Control):** Distilled water only.
- **Group 2 (HgCl₂):** 3 mg/kg HgCl₂ daily.
- **Group 3 (A. heterophyllus):** 1000 mg/kg extract daily.
- **Group 4 (A. heterophyllus + HgCl₂):** 1000 mg/kg extract followed 30 min later by 3 mg/kg HgCl₂.
- **Group 5 (Vitamin E + HgCl₂):** Vitamin E (200 mg/kg) followed 30 min later by 3 mg/kg HgCl₂.

All treatments were administered orally using an oral gavage once daily for 28 days. Body weights were recorded weekly.

Phytochemical Analysis

Phytochemical Screening and Quantification

Quantitative phytochemical analysis of the aqueous *Artocarpus heterophyllus* fruit extract was performed using standard spectrophotometric methods to determine the concentrations of major antioxidant-related constituents (Thapa *et al.*, 2016).

Sample Collection and Organ Weights

At the end of the experiment, animals were anaesthetized using ketamine (80 mg/kg). Cardiac puncture was used to obtain blood samples. The heart and pancreas were excised, trimmed of fat, rinsed in ice-cold saline, blotted dry, and weighed using a digital balance.

Organ-to-body weight index was calculated as:

$$\text{Organ index} = \frac{\text{Organ weight (g)}}{\text{Body weight (g)}} \times 100$$

Biochemical Assays

Preparation of Serum Samples

Blood collected by cardiac puncture was transferred into plain sample tubes and allowed to clot at room temperature. The clotted samples were centrifuged at 3000 rpm for 10 minutes to obtain clear serum. The serum supernatant was carefully aspirated into sterile microtubes and stored at -20°C until biochemical analysis. All oxidative stress markers, including superoxide dismutase (SOD), catalase (CAT), glutathione peroxidase (GPx), and malondialdehyde (MDA) were measured directly from the serum samples using established spectrophotometric methods.

Assay of Oxidative-Stress Markers

- **Superoxide Dismutase (SOD):** Measured by the epinephrine auto-oxidation method (Chukwu *et al.*, 2023).
- **Catalase (CAT):** Determined by monitoring the decomposition rate of hydrogen peroxide (Trawczyńska, 2020)
- **Glutathione Peroxidase (GPx):** Assayed using the Ahmed *et al.* (2021) protocol.
- **Malondialdehyde (MDA):** Estimated using the thiobarbituric acid reaction method (De Lean and Borges, 2020) as an index of lipid peroxidation.

Serum Lipid Profile

Serum concentrations of total cholesterol, triglycerides, HDL-cholesterol, and LDL-cholesterol were determined using commercial diagnostic kits (Randox® Laboratories).

Histological Examination

Heart and pancreas samples were fixed in 10% buffered formalin, dehydrated, cleared, and embedded in paraffin. Serial sections (5 μm) were cut and stained with hematoxylin and eosin (H&E) following standard protocols. Slides were examined under a light microscope (400x), and photomicrographs were captured using a digital microscope camera.

Statistical Analysis

Statistical analysis was performed using GraphPad Prism (Version 9). Results were expressed as mean \pm SEM. Group comparisons were conducted using one-way ANOVA followed by the Tukey's post-hoc test. A p -value < 0.05 was considered statistically significant.

RESULTS

Phytochemical Composition of the Extract

Quantitative phytochemical analysis revealed that the extract contained appreciable levels of antioxidant-related constituents. Total phenolics were the most

abundant phytochemicals detected, followed by saponins and flavonoids. Detailed values are presented in Table 1.

Body Weight and Organ Weights

All twenty-five rats completed the experimental period. The initial and final body weights for each group are presented in Table 2. Within-group comparisons showed variable weight changes, with statistically significant increases in the control, 1000 mg/kg *Artocarpus heterophyllus* extract, jackfruit + HgCl₂, and vitamin E + HgCl₂ groups ($p < 0.05$), while the HgCl₂-only group showed minimal change. Heart and pancreas weights, as well as organ-to-body weight indices, did not differ significantly among groups ($p > 0.05$), as shown in Table 3.

Serum Oxidative Stress Markers

Serum oxidative stress parameters demonstrated measurable group differences (Table 4). SOD and catalase levels were lower in the HgCl₂ group compared with the control, while GPx values showed no significant group variation ($p > 0.05$). MDA levels were highest in rats administered HgCl₂ alone and lower in groups that received *A. heterophyllus* extract or vitamin E prior to HgCl₂ exposure. Overall ANOVA showed significant differences for SOD, catalase, and MDA ($p < 0.05$).

Serum Lipid Profile

Serum lipid values (total cholesterol, triglycerides, LDL-C, and HDL-C) varied across treatment groups, as summarized in Table 5. HgCl₂-treated rats exhibited lower total cholesterol and HDL-C and higher triglycerides compared with controls. Groups receiving *A. heterophyllus* extract or vitamin E showed values that differed significantly from the HgCl₂ group across several lipid parameters ($p < 0.05$ for all ANOVA comparisons).

Histological Findings

Heart

HgCl₂ exposure produced interstitial haemorrhage and vascular congestion in cardiac tissue. These changes were absent in extract-only animals and markedly reduced in both extract+HgCl₂ and vitamin E+HgCl₂ groups, where myocardial architecture appeared largely preserved (Figure 1).

Pancreas

Pancreatic sections from HgCl₂-treated rats showed vascular congestion and mild inflammatory infiltration. Pre-treatment with *A. heterophyllus* or vitamin E preserved acinar organization and islet morphology with only minimal vascular changes (Figure 2).

A full summary of all numerical and histological findings is presented in the accompanying tables and figures.

Table 1. Quantitative Phytochemical Composition of *Artocarpus heterophyllus* Extract.

Phytochemical	Mean ± SEM
Alkaloids (mg/g)	0.70 ± 0.09
Tannins (mg/g)	4.7 ± 0.41
Total Phenolics (mg/g)	29 ± 0.48
Saponins (mg/g)	19 ± 1.1
Flavonoids (mg/g)	5.4 ± 1.2

Values are mean ± SEM (n = 3). Results expressed as mg of constituent per g of dry extract weight.

Table 2. Body Weight Parameters across Experimental Groups.

Parameter / Group	Control	3mg/kg Mercury Chloride	1000mg/kg <i>Artocarpus heterophyllus</i>	1000mg/kg <i>Artocarpus heterophyllus</i> + 3mg/kg Mercury Chloride	Vitamin E + 3mg/kg Mercury Chloride
Initial Weight (g)	188.67 ± 1.45	207.00 ± 6.93	202.67 ± 8.41	211.00 ± 2.96	217.00 ± 7.57
Final Weight (g)	222.33 ± 3.84*	208.00 ± 4.04	231.67 ± 10.42	230.67 ± 0.67*	231.00 ± 7.81
p-value (Within Group)	0.005	0.777	0.018	0.003	0.026
Weight Change (g)	33.67 ± 3.84	1.00 ± 2.52*	29.00 ± 9.07	19.67 ± 1.20#	14.00 ± 5.51#
p-value (vs Control)	—	0.0012	0.897	—	—
p-value (vs Mercury Only)	—	—	—	0.0076	0.038

Note: Data are presented as Mean ± SEM. The within-group p-value represents the result of a paired t-test between initial and final weights. The between-group p-values for weight change were obtained from a one-way ANOVA followed by Tukeys post-hoc test. Bolded values indicate statistical significance (p < 0.05)

Table 3. Heart and Pancreas Weights and Organ-to-Body Weight Ratios.

Parameter / Group	Control	3mg/kg Mercury Chloride	1000mg/kg A. heterophyllus	1000mg/kg <i>Artocarpus heterophyllus</i> + 3mg/kg Mercury Chloride	Vitamin E + 3mg/kg Mercury Chloride	p-value
Heart Weight (g)	0.767 ± 0.145	0.533 ± 0.067	0.467 ± 0.033	0.700 ± 0.100	0.700 ± 0.115	0.333
Pancreas Weight (g)	0.800 ± 0.153	0.667 ± 0.186	0.967 ± 0.067	0.833 ± 0.033	0.633 ± 0.033	0.463
Heart-to-Body Weight Ratio (%)	0.345 ± 0.064	0.257 ± 0.033	0.201 ± 0.006	0.303 ± 0.043	0.302 ± 0.046	0.291
Pancreas-to-Body Weight Ratio (%)	0.359 ± 0.067	0.321 ± 0.089	0.418 ± 0.024	0.361 ± 0.013	0.275 ± 0.016	0.483

Note: Values are expressed as mean ± SEM. The p-values are from one-way ANOVA comparing all groups. None of the parameters showed statistically significant differences among groups (p > 0.05 for all comparisons).

Table 4: Serum Oxidative Stress Parameters.

Parameter/Group	Control	3mg/kg Mercury Chloride	1000mg/kg <i>Artocarpus heterophyllus</i>	1000mg/kg <i>Artocarpus heterophyllus</i> + 3mg/kg Mercury Chloride	Vitamin E + 3mg/kg Mercury Chloride	p-value
Superoxide Dismutase (SOD)	0.464 ± 0.015	0.197 ± 0.010*	0.578 ± 0.009	0.508 ± 0.026	0.550 ± 0.063	<0.001
Catalase	0.314 ± 0.007	0.163 ± 0.018*	0.365 ± 0.041	0.239 ± 0.032	0.323 ± 0.010	0.012
Glutathione Peroxidase (GPx)	1.074 ± 0.031	0.965 ± 0.045	1.151 ± 0.073	1.059 ± 0.010	1.060 ± 0.035	0.067
Malondialdehyde (MDA)	0.0906 ± 0.0081	0.1691 ± 0.0194*	0.0786 ± 0.0048	0.0967 ± 0.0224	0.0529 ± 0.0032#	<0.001

Note: Values are expressed as mean ± SEM. *P<0.05 compared with the control group; #P<0.05 compared with the 3mg/kg Mercury Chloride only group based on Tukey's HSD post-hoc test following one-way ANOVA.

Table 5. Lipid Profile Parameters across Experimental Groups.

Parameter/Group	Control	3mg/kg Mercury Chloride	1000mg/kg <i>Artocarpus heterophyllus</i>	1000mg/kg <i>Artocarpus heterophyllus</i> + 3mg/kg Mercury Chloride	Vitamin E + 3mg/kg Mercury Chloride	P-value
Total Cholesterol	96.33 ± 1.45	76.00 ± 2.52*	92.33 ± 1.45	86.00 ± 1.15#	91.67 ± 1.20#	<0.001
Triglyceride	105.67 ± 1.20	177.67 ± 1.45*	120.67 ± 1.76	152.33 ± 1.45#	132.33 ± 1.45#	<0.001
HDL	50.33 ± 0.88	31.67 ± 0.67*	45.67 ± 2.03	36.33 ± 1.86	43.33 ± 2.03#	<0.001
LDL	34.67 ± 1.86	22.67 ± 1.20*	29.00 ± 0.58	36.67 ± 1.76#	34.00 ± 0.58#	<0.001

Note: Values are expressed as mean ± SEM. * $P < 0.05$ compared with the control group; # $P < 0.05$ compared with the 3mg/kg Mercury Chloride only group based on Tukey's HSD post-hoc test following one-way ANOVA.

Histology

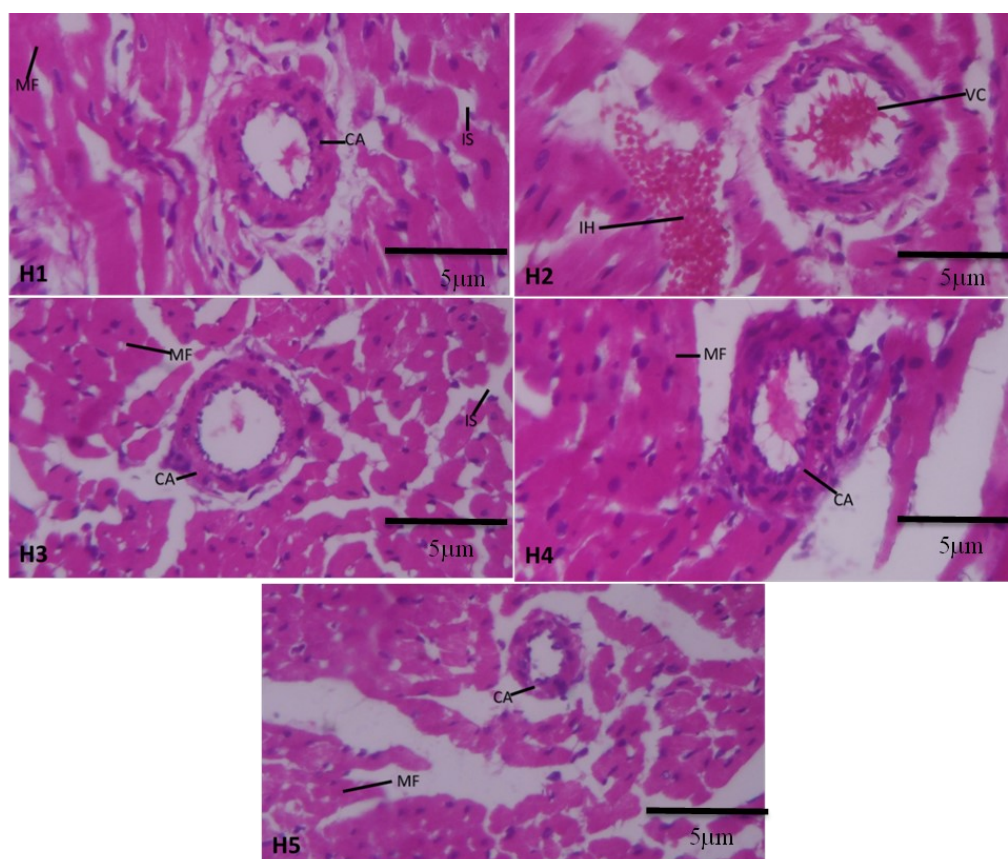


Figure 1. The control rat hearts (Plate H1) displayed normal myocardial architecture characterized by well-organized bundles of myocardial fibres, intact interstitial spaces, and clearly defined coronary arteries. Hearts from rats exposed to mercury chloride alone (Plate H2) showed evidence of interstitial haemorrhage and vascular congestion, indicating marked structural disruption. In the group treated with 1000 mg/kg jackfruit extract only (Plate H3), the myocardium retained normal histological features, with well-arranged cardiomyocyte bundles, preserved interstitial spaces, and intact coronary vessels. Rats pre-treated with jackfruit extract before mercury chloride administration (Plate H4) also exhibited normal cardiomyocyte bundles and preserved coronary artery structure, suggesting substantial protective effects against $HgCl_2$ -induced damage. Similarly, the vitamin E pre-treated group (Plate H5) showed normal myocardial architecture with intact cardiomyocyte bundles and coronary arteries, further indicating mitigation of mercury-induced cardiac injury.

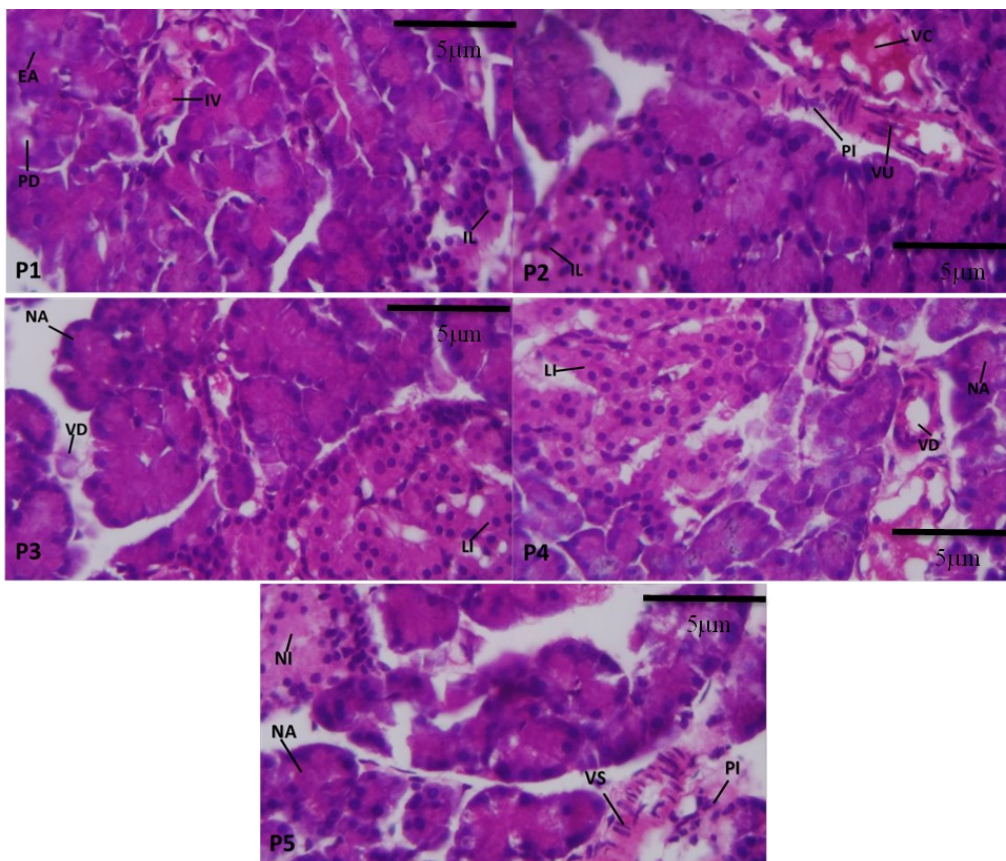


Figure 2. The pancreas of the control rats (Plate P1) showed normal histological features, including well-arranged exocrine acini, distinct pancreatic ducts, interlobar vessels, and clearly defined islets of Langerhans. In contrast, rats administered mercury chloride alone (Plate P2) exhibited vascular congestion, areas of ulceration, and mild perivascular inflammatory cell infiltrates, although the islets of Langerhans remained identifiable. Animals treated with jackfruit extract only (Plate P3) demonstrated normal acinar architecture, prominent and luxuriant islets of Langerhans, and noticeable vasodilatation. Similarly, rats pre-treated with 1000 mg/kg jackfruit extract before mercury chloride exposure (Plate P4) showed preserved acini, vasodilatation, and luxuriant islets, indicating marked tissue protection. In the vitamin E pre-treated group (Plate P5), the pancreas showed normal acini and islets, with mild perivascular inflammatory infiltrates and areas of vascular stenosis.

DISCUSSION

This study evaluated the protective effects of *Artocarpus heterophyllus* extract against mercury chloride-induced toxicity in the heart and pancreas of Wistar rats. The findings demonstrate that HgCl_2 caused clear biochemical, lipid profile, and histopathological alterations, despite the absence of significant changes in organ weights.

Phytochemical constituents

The phytochemical analysis demonstrated that the extract is particularly rich in phenolic compounds and flavonoids, both of which are widely recognized for their free-radical scavenging and metal-chelating properties. These constituents likely contributed to the observed reduction in lipid peroxidation and preservation of antioxidant enzyme activity in treated animals. The presence of saponins and tannins may also support membrane stabilization and anti-inflammatory effects, further contributing to tissue protection (Table 1).

These findings are consistent with previous reports on *Artocarpus heterophyllus*, which have documented high phenolic and flavonoid content in different parts of the plant (Ilmi *et al.*, 2020) and linked these compounds to strong antioxidant capacity and protective effects against oxidative damage in experimental models. Earlier phytochemical studies have shown that jackfruit extracts possess significant radical-scavenging activity and lipid peroxidation inhibitory potential, largely attributed to polyphenolic constituents such as quercetin derivatives and other flavonoids (Anvar *et al.*, 2020; Gupta *et al.*, 2023). Similar protective effects of phenolic-rich plant extracts against heavy-metal-induced oxidative stress have also been widely reported (Hithamani *et al.*, 2023), supporting the role of these bioactive compounds in mitigating mercury-associated cellular injury. Thus, the present findings align with established literature and provide further evidence that the antioxidant phytochemical profile of *A. heterophyllus* underlies its observed cardiopancreatic protective effects.

Body Weight and Organ Weights

Across groups, heart and pancreas weights, as well as the corresponding organ-to-body weight ratios, did not differ significantly ($p > 0.05$). This indicates that HgCl₂ did not induce gross organ atrophy or hypertrophy, even though significant biochemical and histological changes were present. Similar dissociation between organ mass and microscopic injury has been reported in mercury-exposed rodents, where toxicity manifests initially at the cellular level rather than through changes in tissue mass (Massányi *et al.*, 2020). Notably, body weight gain was significantly reduced in the HgCl₂ group relative to controls, suggesting systemic stress or metabolic disturbance (Table 2), an effect consistent with previous experimental findings (Al-Aziz *et al.*, 2024).

Serum oxidative stress

The serum oxidative stress revealed a clear disruption of antioxidant homeostasis following exposure to mercuric chloride. Rats treated with 3 mg/kg HgCl₂ showed a significant reduction in SOD and catalase activities compared with the control group, consistent with the well-documented ability of mercury to inhibit antioxidant enzymes through thiol-binding and free-radical generation (Ali *et al.*, 2020). The associated elevation in MDA levels further confirms lipid peroxidation and oxidative membrane injury, supporting earlier toxicological reports that identify MDA as a reliable indicator of mercury-induced cellular damage (Elblehi *et al.*, 2019).

In contrast, animals pre-treated with *Artocarpus heterophyllus* extract maintained near-normal SOD, catalase, GPx, and MDA values, indicating substantial protection against mercury-induced oxidative imbalance. This preservation of enzymatic activity aligns with previous findings describing *A. heterophyllus* phytochemicals, particularly flavonoids and phenolic acids as potent free-radical scavengers capable of stabilizing reactive oxygen species and supporting endogenous antioxidant systems (Sreeja *et al.*, 2021). Similarly, vitamin E pre-treatment significantly reduced MDA levels compared with the HgCl₂-only group, highlighting its membrane-stabilizing and chain-breaking antioxidant effects (Zimmer *et al.*, 2023).

Lipid Profile Alterations

HgCl₂ exposure produced dyslipidemia, with significant increases in triglycerides and reductions in HDL, alongside reductions in total cholesterol and LDL relative to controls (Table 5). Experimental mercury exposure has previously been associated with disrupted lipid metabolism, potentially through oxidative modification of lipoproteins and altered hepatic lipid handling (Queiroz *et al.*, 2024).

Both *A. heterophyllus* extract and vitamin E demonstrated corrective effects, significantly improving HDL, LDL, triglycerides, and total cholesterol values compared with the mercury-only group. This suggests

that the extract possesses hypolipidemic or lipid-stabilizing activity, an effect attributed in literature to its flavonoids and antioxidant micronutrients, which reduce lipid peroxidation and modulate lipid-regulating enzymes (Ansari *et al.*, 2025).

Histopathological Findings

Histological evaluation of the heart and pancreas provides strong structural evidence of mercury toxicity. Hearts from the HgCl₂ group showed interstitial hemorrhage and vascular congestion (Figure 1), while the pancreas exhibited vascular congestion, ulceration, and inflammatory infiltrates (Figure 2). These lesions support the biochemical evidence of oxidative injury and reflect previously described microvascular and parenchymal changes associated with mercury exposure in experimental models (Takahashi and Shimohata, 2019; Draper *et al.*, 2023).

Importantly, rats pre-treated with *A. heterophyllus* extract showed preserved myocardial fibers, intact coronary vessels, and well-organized pancreatic acini and islets, comparable to controls. Vitamin E showed similar but slightly less complete protection. These morphological findings support the antioxidant data, suggesting that the extract prevented free radical damage, stabilizes microvasculature, and maintains cellular integrity under toxic insult.

Overall Interpretation

Taken together, the biochemical and histological findings confirm that HgCl₂ induces systemic oxidative stress, dysregulated lipid metabolism, and structural injury in the heart and pancreas. Pre-treatment with *Artocarpus heterophyllus* extract provided broad protection, normalizing serum oxidative stress markers, improving lipid parameters, and preserving tissue integrity more effectively than mercury exposure alone. Vitamin E demonstrated similar protective trends, although the effects of *Artocarpus heterophyllus* were in several cases more pronounced. These results support the antioxidant and cytoprotective potential of the jackfruit leaf extract in mercury toxicity. Nonetheless, the study is limited by the use of single-dose regimens and the absence of molecular mechanistic assays. Future investigations employing multiple dosing levels, longer exposure periods, and expanded biochemical and molecular endpoints are necessary to further validate the protective mechanisms of *Artocarpus heterophyllus* and its translational applicability.

Study Limitations

This study is limited by the use of single doses of HgCl₂, *A. heterophyllus* extract, and vitamin E, preventing dose-response analysis. Only antioxidant markers were measured; additional molecular assays (e.g., inflammatory cytokines, apoptotic markers) would have strengthened mechanistic interpretation. Despite these limitations, the results clearly demonstrate both the toxic

effects of mercury and the protective potential of *A. heterophyllum* extract.

CONCLUSION

The present study demonstrates that oral exposure to mercuric chloride produced marked biochemical disturbances, including reduced serum antioxidant enzyme activities and increased lipid peroxidation, alongside alterations in serum lipid profile. These biochemical changes were accompanied by notable histological injury in both the heart and pancreas. Pre-treatment with *Artocarpus heterophyllum* extract or vitamin E significantly improved serum oxidative stress markers, moderated dyslipidemia, and preserved tissue architecture, indicating meaningful protection against mercury-induced toxicity. The combined biochemical and histological findings highlight the therapeutic potential of *Artocarpus heterophyllum* as a natural antioxidant. Further studies incorporating molecular markers, expanded dosing ranges, and larger sample sizes are recommended to clarify mechanistic pathways and strengthen translational relevance.

Availability of data and materials: The data can be obtained from the corresponding author upon reasonable request by contacting them through their email ID.

Acknowledgements: None.

Funding: None.

Authors Contribution: Edobor Obayuwana: Methodology, Supervision and project administration. All authors have read and agreed to the published version of the manuscript. Joseph Raymond Enoghase: Investigation, Resource, Data curation, writing review and editing and visualization.

Consent for publication: Not applicable.

Competing interests: None.

Ethics approval and consent to participate: The Research Ethics Committee's guidelines for animal handling and treatment at the University of Benin's College of Medical Sciences was fully implemented and ethical approval number CMS/REC/2024/793 was assigned

REFERENCES

- Ahmed, A. Y., Aowda, S. A., & Hadwan, M. H. (2021). A validated method to assess glutathione peroxidase enzyme activity. *Chemical Papers*, 75(12), 6625-6637.
- Ajiboye, B. O., Ojo, O. A., Adeyonu, O., Imiere, O., Olayide, I., Fadaka, A., & Oyinloye, B. E. (2016). Inhibitory effect on key enzymes relevant to acute type-2 diabetes and antioxidative activity of ethanolic extract of *Artocarpus heterophyllum* stem bark. *Journal of acute disease*, 5(5), 423-429.
- Ali, S. A., Kadhem, M. A., & Ali, H. A. (2020). Protective effect of ethanolic extract of *Zingiber Officinale* against mercuric chloride induced renal toxicity in rats. *Indian Journal of Public Health*, 11(03), 799.
- Ansari, P., Islam, S. S., Ali, A., Masud, M. S. R., Reberio, A. D., Khan, J. T., ... & Abdel-Wahab, Y. H. (2025). Insulinotropic and Beta-Cell Proliferative Effects of Unripe *Artocarpus heterophyllum* Extract Ameliorate Glucose Dysregulation in High-Fat-Fed Diet-Induced Obese Mice. *Diabetology*, 6(8), 83.
- Anvar Hussain, N. A., Hoque, M., Agarwal, S., Syed, I., & Raihan, M. (2020). Jackfruit (*Artocarpus heterophyllum*). In *Antioxidants in Fruits: Properties and Health Benefits* (pp. 461-477). Singapore: Springer Singapore.
- Balali-Mood, M., Naseri, K., Tahergorabi, Z., Khazdair, M. R., & Sadeghi, M. (2021). Toxic mechanisms of five heavy metals: mercury, lead, chromium, cadmium, and arsenic. *Frontiers in pharmacology*, 12, 643972.
- Bondy, S. C. (2017). Metals and neuroinflammation. In *Biomarkers in Neurodegenerative Diseases* (pp. 83-93). Academic Press.
- Chukwu, L. C., Nweze, S. O., Ogabido, C. A., Mansur, A., Nwankwo, M. E., Chukwuka, B. U., ... & Obianagha, K. U. (2023). Superoxide dismutase activity levels in parturients on intermittent preventive treatment with sulphadoxine pyrimethamine and their controls at current confinements. *World Journal of Biology Pharmacy and Health Sciences*, 14(2), 190-199.
- De Leon, J. A. D., & Borges, C. R. (2020). Evaluation of oxidative stress in biological samples using the thiobarbituric acid reactive substances assay. *Journal of visualized experiments: JoVE*, (159), 10-3791.
- Draper, M., Bester, M., Van Rooy, M., & Oberholzer, H. (2023). Adverse pulmonary effects after oral exposure to copper, manganese and mercury, alone and in mixtures, in a Sprague-Dawley rat model. *Ultrastructural Pathology*, 47(3), 146-159.
- El-Aziz, A., Yasmin, M., Kazlak, M. M., Farouk, N. H., Helmy, M. M., Mohamed, A. R., ... & Abu Almaaty, A. H. (2024). Protective effects of Turbo *Cornutus* extract against HgCl₂-induced pathological changes in albino rat tissues. *Catrina: The International Journal of Environmental Sciences*, 31(1), 87-98.
- Elblehi, S. S., Hafez, M. H., & El-Sayed, Y. S. (2019). L- α -Phosphatidylcholine attenuates mercury-induced hepato-renal damage through suppressing oxidative stress and inflammation. *Environmental Science and Pollution Research*, 26(9), 9333-9342.
- Enoghase, J. R., Obayuwana, E., & Osarinmwian, B. I. (2025). The protective role of Vitamin E against copper-induced histopathological changes in rat rectum: An experimental study. *Global Journal of Health Sciences and Research*• Volume, 3(2), 80.
- Genchi, G., Sinicropi, M. S., Carocci, A., Lauria, G., & Catalano, A. (2017). Mercury exposure and heart diseases. *International journal of environmental research and public health*, 14(1), 74.
- Gupta, A., Marquess, A. R., Pandey, A. K., & Bishayee, A. (2023). Jackfruit (*Artocarpus heterophyllum* Lam.) in health and

- disease: a critical review. *Critical reviews in food science and nutrition*, 63(23), 6344-6378.
- Han, B., Lv, Z., Han, X., Li, S., Han, B., Yang, Q., ... & Zhang, Z. (2022). Harmful effects of inorganic mercury exposure on kidney cells: mitochondrial dynamics disorder and excessive oxidative stress. *Biological Trace Element Research*, 200(4), 1591-1597.
- Hithamani, G., Naveen, J., & Pushpalatha, H. G. (2023). Phenolic compounds: stress markers of plants and their protective role. In *Plant Metabolites under Environmental Stress* (pp. 249-276). Apple Academic Press.
- Hossain, K. R., Akter, S., Nanjeba, M., & Mahmud, M. A. (2024). Properties and performance of biopolymers in textile applications. In *Biopolymers in the Textile Industry: Opportunities and Limitations* (pp. 41-86). Singapore: Springer Nature Singapore.
- Ilmi, H. M., Elya, B., & Handayani, R. (2020). Association between total phenol and flavonoid contents in *Artocarpus heterophyllus* (jackfruit) bark and leaf extracts and lipoxygenase inhibition. *International Journal of Applied Pharmaceutics*, 12(1), 252-256.
- Maqbool, F., Bahadar, H., Niaz, K., Baeri, M., Rahimifard, M., Navai-Nigjeh, M., ... & Abdollahi, M. (2016). Effects of methyl mercury on the activity and gene expression of mouse Langerhans islets and glucose metabolism. *Food and Chemical Toxicology*, 93, 119-128.
- Martins, A. C., Santos, A. A., Lopes, A. C., Skalny, A. V., Aschner, M., Tinkov, A. A., & Paoliello, M. (2021). Endothelial dysfunction induced by cadmium and mercury and its relationship to hypertension. *Current Hypertension Reviews*, 17(1), 14-26.
- Massányi, P., Massányi, M., Madeddu, R., Stawarz, R., & Lukáč, N. (2020). Effects of cadmium, lead, and mercury on the structure and function of reproductive organs. *Toxics*, 8(4), 94.
- Obayuwana, E., & Nweke, S. M. (2024). Ameliorative effect of vitamin E on copper sulfate-induced liver damage in Wistar rats. *Journal of Experimental and Clinical Anatomy*, 21(2), 220-226.
- Okoduwa, S. I. R., Umar, I. A., James, D. B., Inuwa, H. M., & Habila, J. D. (2016). Evaluation of extraction protocols for anti-diabetic phytochemical substances from medicinal plants. *World journal of diabetes*, 7(20), 605.
- Osarinmwian I.B., & Ehimigbai A.R.O. (2025). Protective effect of aqueous *Artocarpus heterophyllus* (jack fruit) extract on bisphenol A-induced nephrotoxicity in adult wistar rats. *Dutse Journal of Pure and Applied Sciences*, 11(3e), 274-281.
- Queiroz, M. I., Lazaro, C. M., Dos Santos, L. M., Rentz, T., Virgilio-da-Silva, J. V., Moraes-Vieira, P. M., ... & Oliveira, H. C. (2024). In vivo chronic exposure to inorganic mercury worsens hypercholesterolemia, oxidative stress and atherosclerosis in the LDL receptor knockout mice. *Ecotoxicology and Environmental Safety*, 275, 116254.
- Ramli, A. N. M., Badruzaman, S. Z. S., Hamid, H. A., & Bhuyar, P. (2021). Antibacterial and antioxidative activity of the essential oil and seed extracts of *Artocarpus heterophyllus* for effective shelf-life enhancement of stored meat. *Journal of Food Processing and Preservation*, 45(1), e14993.
- Saha, S., Sarker, M., Haque, A. R., Nayeem, T. A., & MAUKKEEB, A. R. (2022). A review on tropical fruit: jackfruit (*Artocarpus heterophyllus*). *Asian Journal of Advances in Research*, 5(1), 298-307.
- Sreeja Devi, P. S., Kumar, N. S., & Sabu, K. K. (2021). Phytochemical profiling and antioxidant activities of different parts of *Artocarpus heterophyllus* Lam.(Moraceae): A review on current status of knowledge. *Future Journal of Pharmaceutical Sciences*, 7(1), 30.
- Takahashi, T., & Shimohata, T. (2019). Vascular dysfunction induced by mercury exposure. *International journal of molecular sciences*, 20(10), 2435.
- Thapa, N., Thapa, P., Bhandari, J., Niraula, P., Shrestha, N., & Shrestha, B. G. (2016). Study of phytochemical, antioxidant and antimicrobial activity of *Artocarpus heterophyllus*. *Nepal Journal of Biotechnology*, 4(1), 47-53.
- Trawczyńska, I. (2020). New method of determining kinetic parameters for decomposition of hydrogen peroxide by catalase. *Catalysts*, 10(3), 323.
- Yuliana, I., Prenggono, M. D., & Oktavianti, I. K. (2024). Mercury: Its role in endoplasmic reticulum stress of pancreatic beta cells in the incident of diabetes mellitus. *Revista Latinoamericana de Hipertension*, 19(4), 175-182.
- Zimmer, G., Thürich, T., & Scheer, B. (2023). Membrane fluidity and vitamin E. In *Vitamin E in health and disease* (pp. 207-222). CRC Press.

THIS PAGE INTENTIONALLY LEFT BLANK